

MASSACHUSETTS INSTITUTE OF TECHNOLOGY  
ARTIFICIAL INTELLIGENCE LABORATORY

A.I. Memo No. 637

June, 1981

**EVIDENCE RELATING SUBJECTIVE CONTOURS  
AND INTERPRETATIONS INVOLVING OCCLUSION**

Kent A. Stevens

**ABSTRACT.** Subjective contours, according to one theory, outline surfaces that are apparently interposed between the viewer and background (because of the disruption of background figures, sudden termination of lines, and other occlusion "cues") but are not explicitly outlined by intensity discontinuities. This theory predicts that if occlusion cues are not interpreted as evidence of occlusion, no intervening surface need be postulated, hence no subjective contours would be seen. This prediction, however, is difficult to test because observers normally interpret the cues as occlusion evidence and normally see the subjective contours. This article describes a patient with visual agnosia who is both unable to make the usual occlusion interpretations and is unable to see subjective contours. He has, however, normal ability to interpret standard visual illusions, stereograms, and in particular, stereogram versions of the standard subjective contour figures, which elicit to him strong subjective edges in depth (corresponding to the subjective contours viewed in the monocular versions of the figures).

**Acknowledgements:** This report describes research done at the Artificial Intelligence Laboratory of the Massachusetts Institute of Technology. Support for the laboratory's artificial intelligence research is provided in part by the Advanced Research Projects Agency of the Department of Defense under Office of Naval Research contract N00014-80-C-0505 and in part by the AFOSR and NSF grant 79-23110MCS.

## 1. Introduction

Subjective contours, also termed illusory or cognitive contours, are clearly constructions of the human visual system: an intensity edge is perceived where no contrast is objectively present. The circular disk in figure 1 is an example. Subjective contours are generally thought to be generated by the visual system in order to represent implicit surface edges (Lawson and Gulick 1967; Coren 1972; Gregory 1972; Kanizsa 1974). The traditional demonstration consists of a surface that is apparent only by the disruption and partial obliteration of the background (incomplete figures, sudden line terminations, and so forth, sometimes called "occlusion cues"). Coren (1972) suggests that the cues are used only if postulating an occluding surface would allow a simpler overall interpretation of the figure. Gregory (1972) also discusses the cue-and-hypothesis aspect of this process [*cf.* "unconscious inference" (Helmholtz 1925) and (Rock and Anson 1979)]. In figure 1, for instance, the line terminations form a smooth path, and may be interpreted as occlusion by an opaque white circular disk. Roughly speaking, one achieves a simple and coherent explanation of the image by postulating an opaque surface delimited by subjective contours.<sup>1</sup> If subjective contours represent implicit surface boundaries, they may be related to the subjective depth edges seen in stereograms (Shipley 1965; Lawson and Gulick 1967; Blomfield 1973; Gregory and Harris 1974; Julesz and Frisby 1975).

The illusory contrast has been attributed to artifacts of early visual processing analogous to simultaneous contrast (Brigner and Gallagher 1974; Frisby and Clatworthy 1975; Kennedy and Lee 1976). But these suggestions have difficulty accounting for subjective contours being contingent on the particular 3-D interpretation taken, particularly in instances of ambiguous subjective contour figures (Blomfield 1973; Coren and Theodor 1975; Bradley and Dumais 1975; Kennedy 1976; Kennedy and Lee 1976; Bradley and Petry 1977), see also (Brussel *et al.* 1977). Other proposed explanations of the anomalous contrast and brightness involve attention (Kennedy 1976) [*cf.* (Festinger *et al.* 1970; Coren and Theodor 1975)] and figure-versus-ground (Coren 1969; Bradley and Dumais 1975; Marr 1976).




Figure 1. The central region is usually seen as brighter and bounded by a subjective contour. The visual interpretation is of an opaque disk occluding a radial arrangement of lines.

---

1. Since apparent occlusion is the usual evidence for a subjective surface, the subjective contour usually corresponds to a depth discontinuity, but Kennedy (1975) suggests it can also correspond to a crease or boundary between abutted surfaces.

This article examines a prediction that follows from the following two postulates of the above theory: (i) that subjective contours are intentionally generated to represent surface edges, and (ii) surface edges are generated in order to account for apparent occlusion. The following contrapositive is predicted: *when the occlusion cues are not interpreted as evidence for an interposed surface, one does not see subjective contours.* This is not to say that apparent occlusion is a necessary condition for seeing a subjective contour, as Kennedy (1975), Rock and Anson (1979) and others point out. But in instances where the only evidence for the subjective surface is its apparent occlusion of background, the theory is that seeing subjective contours is predicated on taking the occlusion interpretation.

The contrapositive is difficult to test, since the occlusion evidence in these figures is usually compelling and we generally see a subjective surface. The Kanizsa triangle, for instance, is difficult to see merely as a collection of 2-D constructions on the printed page. An important exception, however, is given by ambiguous subjective contour figures which do not force a unique occlusion interpretation (Kennedy 1976; Bradley and Dumais 1975). Here the contrapositive case may be tested, at least informally. In viewing these figures one switches between multiple interpretations, and sees subjective contours associated with the figure currently seen as occluding. Interpretations may be switched by one's volition, and if the figure is taken to be a single planar pattern no subjective contours are seen [see e.g. (Bradley and Dumais 1975, figure 2)]. Those observations are consistent with the contrapositive, but might be regarded as weak support because they are wholly subjective.

We will discuss a patient, J.R., who is both unable to see subjective contours and does not incorporate evidence of occlusion into his visual interpretations. This seems to support the above contrapositive, but careful consideration must be paid to J.R.'s numerous other visual difficulties. However, significant controls are provided by his normal performance on the standard illusions, many of which involve 3-D interpretations (from shading, perspective, and other non-occlusion cues), his ability, given a geometric pattern, to integrate local structure into a global whole, and especially, his normal interpretation of stereogram versions of subjective contour figures, where the depth discontinuities (the stereo counterparts to the subjective contours) were vivid to the patient.

The case reported here is probably not unique, raising the question of whether some segment of the normal population has difficulty interpreting the traditional occlusion cues, and if so, whether they also fail to see subjective contours suggested by the occlusion.

## 2. Experiments

### 2.1 The patient

The patient J.R. is described in (Wapner *et al.* 1978). A summary of that case report is given here. J.R. is a 73 year old male, familiarly left-handed. He suffered a cerebral vascular accident that caused right homonymous hemianopsia, visual recognition difficulties, and a moderate memory disorder. A brain scan showed increased uptake bilaterally in the medial occipital region, greater on the left than on the right. An electroencephalogram showed slowing in the left occipital and temporal region.

His visual acuity was tested to be 20/70 in each eye; his eye movements were normal with no nystagmus or deviation, and he showed normal optokinetic response, accommodation and pupil reactivity. He had some

impairment in visual tracking of sudden unexpected movements, and his visual fields showed significant restrictions in perimetry tests. The upper right quadrant was blind bilaterally, and a localized, moderately dense scotoma was found in the left parafovea, also bilaterally.

J.R.'s verbal reasoning was essentially intact and he was oriented to place, person and time of day. Praxis, left-right orientation and knowledge of body parts was also normal. However he showed severely impaired visual skills involving imagery, spatial knowledge, and memory. Wapner *et al.* (1978) provide examples of J.R.'s drawings which show neglect and overdrawing. When asked to copy an object in a photograph which he did not recognize, the rendition often lacked important contours such as the outline of the object. When drawing an object from memory or from real life, the depiction was clearly drawn but often misproportioned.

An important finding was J.R.'s normal performance on a series of standard illusions: Necker cube, Koffman cubes, Schroder staircase, reversible craters and blisters, corridor, Ponzo, Muller-Lyer, and Hering illusions. Several of these figures involve depth perception, of course.

## 2.2 Observations

The patient's difficulty with subjective contour figures was first noticed by T. Judd and W. Wapner. Judd, Wapner and the author conducted two sessions with the patient. During the first, the patient was shown traditional subjective contour figures (same scale as shown here) viewed at normal reading distance and normal room illumination. Several of those figures were also presented at approximately 5 feet. In addition, J.R. was shown several Glass patterns (Glass 1969) as controls, in order to evaluate J.R.'s ability to see global geometric organization. (Glass patterns are generated by superimposing on a random dot pattern a copy of that pattern that has been transformed, *e.g.* enlarged or rotated, as in figure 2).

The second session examined J.R.'s performance on stereogram versions of subjective contour figures (in the manner of (Blomfield 1973)). Two random dot stereograms, depicting a planar disk and square, were first shown to test his stereo ability. These stereograms were 50% dot density patterns on a 100 by 100 array which subtended roughly 25 by 25 degrees when viewed. All stereograms were presented as transparencies viewed through a *Realist* stereo viewer.




Figure 2. A concentric pattern emerges if one copy of a random dot pattern is rotated (left) and superimposed on the original. The pattern is radial (right) if the copy is scaled relative to the original.

### 2.2.1 Session I

During the first session, the subjective contour figures examined included the Kanizsa triangle and the variant based on a square (Kanizsa 1976), and figures 1 and 3-6. His spontaneous verbal description was cogent and thorough but strangely literal. The Kanizsa triangle, for example, was described as three black shapes and an arrangement of line segments. When asked to elaborate on the black shapes, he described what was literally present (essentially, an incomplete or notched disk). Likewise, the line segments were described merely as disjoint angles or corners. He rejected the suggestion that the corners are the three vertices of a triangle, explaining that the sides were obviously incomplete. It is noteworthy that J.R. could judge that the line segments were collinear on either side of the gap.

Likewise, the spoke pattern (figure 1) was described as "a blank circle with lines going out of it at equal lengths so the end of each line makes another larger circle". When asked about the smaller circle: "it's not a circle, it's just that nothing has been drawn there". This is an accurate description of figure 1, of course, but normally one can see the figure as a white disk occluding the center of a set of radial lines. Yet the patient could not achieve the occlusion interpretation when described to him verbally. Later it came to him as a revelation after the arrangement was physically demonstrated by placing a small disk of paper over a hand-drawn radial line pattern.

Similarly, figure 3 was given a literal and two-dimensional description, as lines whose endpoints lie along an undulating curve. Figure 4 was consistently interpreted as two rectangles on either side of a square, not a square partially occluding a rectangle, even when the latter interpretation was verbally suggested. The entire figure was seen at one depth. The interpretation of a square in front of a rectangle was physically demonstrated with two pieces of paper, and after some effort, he understood how the interpretation could apply to figure 4, at least intellectually. Nonetheless, when asked to draw figure 4, although he took care to duplicate the aspect ratios of the three rectangles, the two lines corresponding to the occluded edges were not made collinear. Figure 5 was described only as an arrangement of irregular black shapes. He never interpreted the ensemble as an opaque pear-shaped blob lying over black disks. In figure 6, which is usually interpreted as a translucent rectangle lying over various-sized black disks, the grey portion of each disk was described by the patient as a separate figure from the black portion. Yet he noticed that the grey and black




Figure 3. The terminated lines give rise to two vertical and one sinusoidal subjective contours. The pattern is usually interpreted as one grid in front of another.

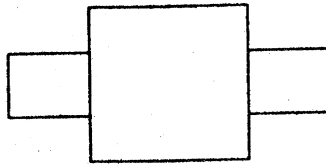


Figure 4. This can be interpreted as a rectangle in front of another, or as three rectangles. The latter interpretation does not take as evidence of occlusion the collinearity of the "background" horizontal lines or their T-junctions against the "occluding" vertical lines.




Figure 5. Evidence of occlusion apparently gives rise to the compelling interpretation of a pear-shaped form in front of a collection of black disks.




Figure 6. Usually interpreted as a translucent rectangle above black disks (Kanizsa 1976).

portions together defined circular forms. He also saw that the grey-black boundaries partially defined the perimeter of a rectangle, analogously to figure 5. But despite his precise descriptions, he did not see the rectangle as occluding, nor did he see the subjective contour.

After recording his description of each figure, J.R.'s attention was directed to where a subjective contour is

usually seen, and he was asked whether any faint brightness edge seemed present. He was told that it might be subtle, but failed to see any illusory effects. J.R. was also asked whether the figure bounded by the subjective contours appeared brighter (or of greater contrast), but the replies were consistently "no". The center of figure 1, for example, usually appears brighter than the surrounds, but did not to the patient.

Finally, J.R. was shown Glass patterns similar to those in figure 2. He had no difficulty in seeing the radial, spiral or circular patterns. The centers of the patterns were noticed immediately, followed by descriptions of the overall organization. The global shape was indicated by gesticulation when J.R. could not recall the appropriate terminology (such as "spiral"). It was clear that his perception of the local organization in these patterns was effortless and normal.

### 2.2.2 Session II

The patient's stereopsis was tested with two random dot stereograms, one of a circular disk against the background, the other a square. Both were successfully fused, with the disk and square described as being suspended in front of the background. The patient could easily resolve the ragged boundaries of the shapes in the random dot stereograms due to the quantization on a square grid.

The patient then viewed stereogram versions of the subjective contour figures, shown in figures 7-10. Figures 7, 8, and 9 were dramatic to the patient, with the disk, square and triangle (bear in mind they are equally implicit in the stereograms) described by the patient as appearing "cut out of white paper and suspended". The edges of these figures were seen as sharp and distinct. Figure 10 presented the patient some difficulty, but was suddenly reported to be a rectangle suspended in front of disks. Figures 11 and 12 are his renditions of figures 9 and 10. Note that his drawings clearly show edges that are not objectively present. These edges correspond to loci along which stereo disparity is discontinuous.

The patient's verbal description of these figures in depth involved occlusion. In figure 8, for example, the background was described as a black cross with additional thin horizontal and vertical lines. The background lines in figure 9 were described as a triangle. J.R.'s descriptions of the stereo figures coincided with the normal or conventional interpretation in sharp contrast to the monocular versions.

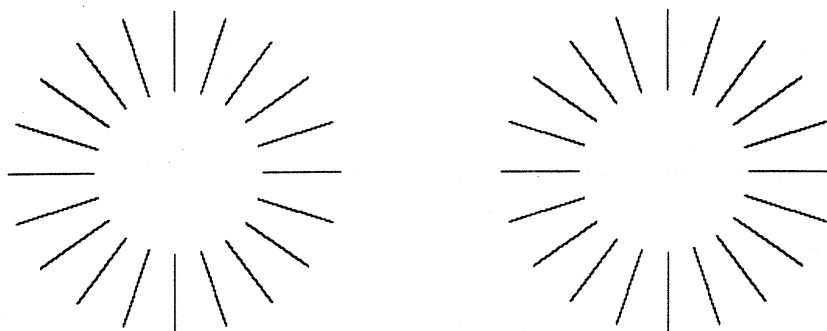


Figure 7. Stereogram version of figure 1.

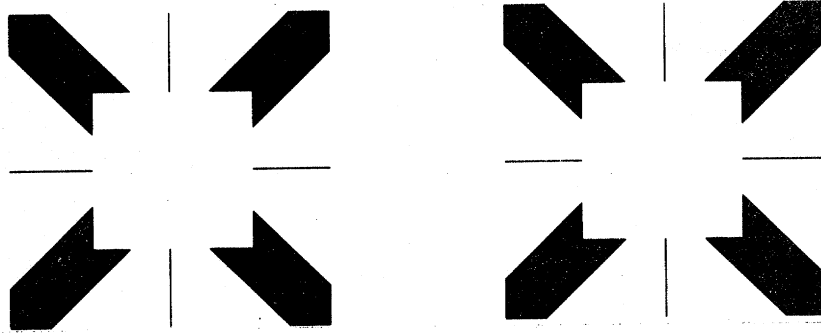


Figure 8. Stereogram version of the cover illustration in (Kanizsa 1976).

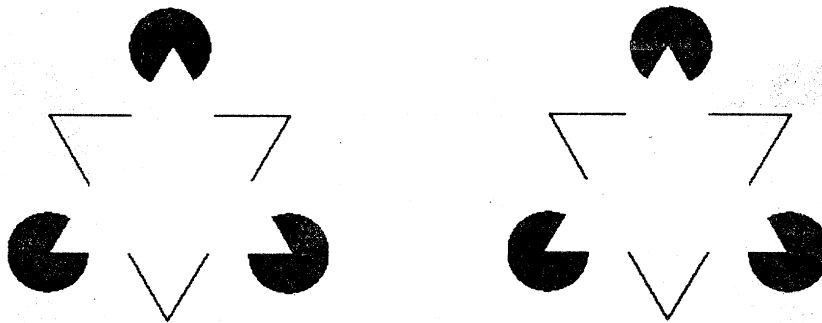


Figure 9. Stereogram version of the Kanizsa triangle (Kanizsa 1976).



Figure 10. Stereogram version of figure 6.

### 3. Discussion

The visual interpretations made by J.R. did not incorporate occlusion evidence, and he did not see subjective contours or illusory subjective figures. These findings are consistent with the contrapositive of the theory that subjective contours are generated to account for implicit evidence of a surface, where apparent occlusion is one source of such evidence. In light of the patient's history, one might dismiss these observations as



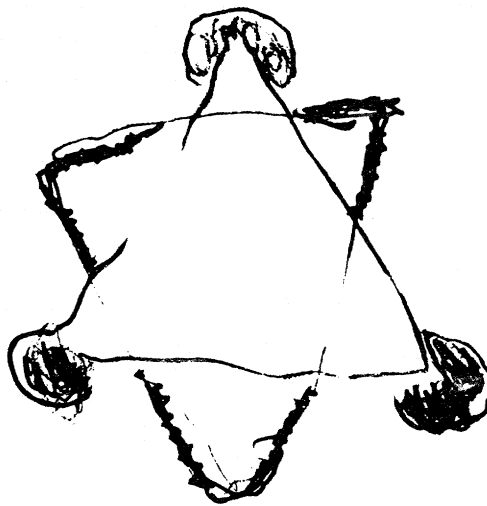


Figure 11. The patient's rendition of the figure 9 stereogram. The triangles were drawn first, followed by the three disks. The background triangle was then emphasized, with an attempt to capture the saw-tooth artifact of the computer-generated stereogram.

---

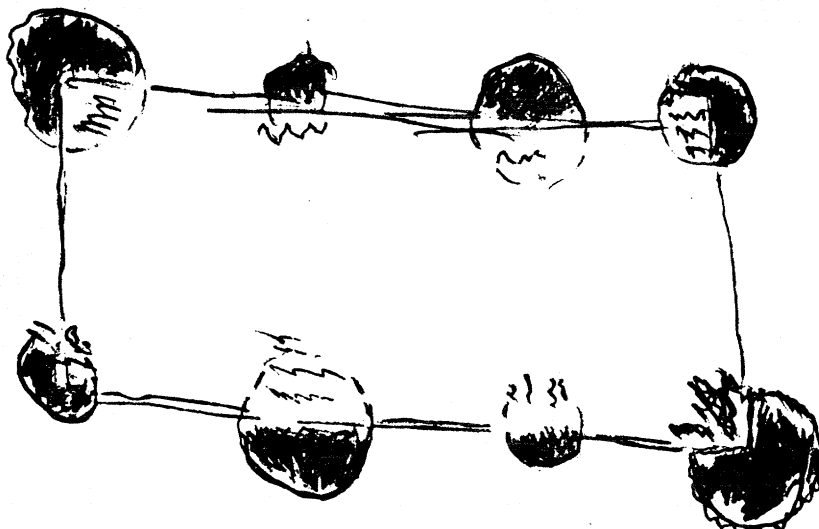


Figure 12. The patient's rendition of the figure 10 stereogram. The rectangle was drawn first, the disks drawn later.

independent and immediate consequences of his other visual defects, if it were not for certain closely related visual abilities that remained intact. Let us first consider some problems posed by J.R.'s visual defects.

Wapner *et al.* (1978) observe that the peripheral scotomata might make scanning eye movements necessary, and suggest that J.R.'s impaired ability for visual retention and the slight impairment of visual tracking that was observed (perhaps, but not necessarily, indicating problems in controlling eye movements), coupled with the tunnel vision, would make the interpretation of subjective contour figures a difficult task. They offer that a normal observer scanning with "an apparatus which provides a restricted field of vision and a very slow scanning speed" (p. 351) roughly mimics the experience reported by J.R.

Regarding the extent of J.R.'s restricted vision, the first quadrant was found to be almost completely blind, but the second and third quadrants were largely intact from the fovea to beyond at least 20 degrees. J.R. viewed subjective contour figures of roughly 5 cm width from roughly 50 cm distance, in which case the figures subtended less than 6 degrees, and could therefore be placed completely in an intact region of the parafovea by a suitable eye position. (And informally, placing the subjective contour at 5 degrees eccentricity enhances the illusory edge.)

Furthermore, the normal performance with Glass patterns demonstrates that J.R. could integrate or combine local information sufficiently well to achieve an immediate and pronounced global impression of structure from the local organization in these patterns. Also, recall that J.R. made normal interpretations of illusion figures (Wapner *et al.* 1978). Since he could make sense of the Necker cube, the Schroder staircase and other line-drawn figures, his inability to successfully interpret the simple configuration in figure 4 is unlikely to be a simple consequence of J.R.'s restricted visual fields, *etc.*<sup>1</sup>

Another factor that should be considered was the patient's moderately poor visual acuity. But informal experimentation with optical defocussing of subjective contours often shows enhancement of the impression of an apparent edge [see also (Ginsberg 1975)]. Hence J.R.'s acuity was unlikely to be a trivial cause for the performance (and also unlikely to have caused his inability to interpret the occlusion evidence).

What makes J.R.'s performance particularly interesting was his ability to see the subjective contours when they were depicted in stereograms. Note that the subjective triangle in figure 9, for instance, is just as implicit as in the monocular case (*e.g.* in either the left or right image alone). The visual system must still interpolate a continuous contour across the gap, since disparity information is provided only in the vicinity of the disks and at the line terminations. The difference between the stereo and the monocular case seems only to lie in the quality of the depth information presented. The disparity information was unambiguous while the monocular "occlusion cues" were ambiguous. Apparently J.R. had normal ability to generate a subjective edge if given sufficient evidence (such as given by stereo disparity) of the edge. Thus it is parsimonious to hypothesize that J.R. suffered a defect in his ability to incorporate the so-called occlusion cues, *i.e.* to interpret local evidence

---

1. This conclusion does not conflict with the conclusion Wapner *et al.* (1978) draw regarding J.R.'s difficulty with visual recognition, which they attribute to a combination of restricted visual fields and hypothesized defects in immediate visual memory and visual imagery. To account for J.R.'s recognition difficulties it is sufficient to hypothesize defects in a recognition buffer, one that allows recognized fragments of an object to be held long enough for the whole to be recognized. That recognition memory could be distinct from immediate visual memories of contours or local organization. In fact, J.R.'s normal performance with Glass patterns and visual illusions, and his frequent comments on rather global properties of other figures (such as the alignment of widely separated lines) suggests that.

for the existence of interposed surfaces. The restricted visual fields and visual memory defects likely contributed to this failure to interpret occlusion, but they only indirectly caused the failure to see the monocular subjective contours.

The experience with this patient raises an interesting question. Is there a fraction of the normal seeing population that would also have difficulty interpreting monocular evidence of occlusion? (That defect might otherwise be undetected since stereopsis usually dominates our visual perception.) If so, does that same population fail to see subjective contours in the monocular case?

**Acknowledgements:** I thank Dr. Howard Gardner for providing access to the facilities at Boston Veterans Administration Hospital for examination of the agnosia patient J.R. Also Dr. Tedd Judd and Wendy Wapner provided helpful assistance. Professor David Marr and Dr. Shimon Ullman provided useful insights. Thanks also to Marilyn Matz for editorial suggestions. The work was performed in part at the Artificial Intelligence Laboratory of the Massachusetts Institute of Technology and in part at the Boston Veterans Administration Hospital, under National Institute of Neurological Diseases, Communication Disorders and Stroke grant 11408. This article is a revision of M.I.T. A.I. Laboratory Memo 363, June 1976.

## References

- Blomfield S, 1973 "Implicit features and stereoscopy" *Nature New Biology* **245** 256
- Bradley D R, Dumais S T, 1975 "Ambiguous cognitive contours" *Nature* **257** 582-584
- Bradley D R, Petry H M, 1977 "Organizational determinants of subjective contours: the subjective Necker cube" *American Journal of Psychology* **90** 253-262
- Brigner W L, Gallagher M B, 1974 "Subjective contour: apparent depth or simultaneous brightness contrast?" *Perceptual and Motor Skills* **38** 1047-1053
- Brussell E M, Stober S R, Bodinger D M, 1977 "Sensory information and subjective contour" *American Journal of Psychology* **90** 145-156
- Coren S, 1969 "Brightness contrast as a function of figure-ground relations" *Journal of Experimental Psychology* **80** 517-524
- Coren S, 1972 "Subjective contours and apparent depth" *Psychological Review* **79** 359-367
- Coren S, Theodor L H, 1975 "Subjective contour: the inadequacy of brightness contrast as an explanation" *Bulletin of the Psychonomic Society* **6** 87-89
- Festinger L, Coren S, Rivers G, 1970 "The effect of attention on brightness contrast and assimilation" *American Journal of Psychology* **83** 189-207
- Frisby J P, Clatworthy J L, 1975 "Illusory contours: curious cases of simultaneous brightness contrast?"

*Perception* 4 349-357

Glass L, 1969 "Moire effect from random dots" *Nature* 223 578-780

Ginsberg A, 1975 "Is the illusory triangle physical or imaginary?" *Nature* 257 219-220

Gregory R L, 1972 "Cognitive contours" *Nature* 238 51-52

Gregory R L, Harris J B, 1974 "Illusory contours and stereo depth" *Perception and Psychophysics* 15 411-416

Helmholtz H, 1925 *Physiological optics*. Vol. 3 (3rd edition translated by J.P. Southall) (New York: Optical Society of America)

Julesz B, Frisby J, 1975 "Some new subjective contours in random-line stereograms" *Perception* 4 145-150

Kanisza G, 1974 "Contours without gradients or cognitive contours?" *Italian Journal of Psychology* 1 93-112

Kanisza G, 1976 "Subjective contours" *Scientific American* 234 48-52

Kennedy J M, 1975 "Depth at an edge, coplanarity, slant depth, change in direction and change in brightness in the production of subjective contours" *Italian Journal of Psychology* 2 107-123

Kennedy J M, 1976 "Attention, brightness, and the constructive eye" in *Vision and artifact* Ed M. Henle (New York: Springer Verlag)

Kennedy J M, Lee H, 1976 "A figure density hypothesis and illusory contour brightness" *Perception* 5 387-392

Lawson R B, Gulick W L, 1967 "Stereopsis and anomalous contour" *Vision Research* 7 271-297

Marr D, 1976 "Early processing of visual information" *Phil. Trans. Roy. Soc. London B* 275 483-519

Rock I, Anson R 1979 "Illusory contours as the solution to a problem" *Perception* 8 665-681

Shipley T, 1965 "Visual contours in homogeneous space" *Science* 150 348-350

Wapner W, Judd T, Gardner H, 1978 "Visual agnosia in an artist" *Cortex* 14 343-364